

Case Report

RETINITIS PIGMENTOSA ASSOCIATED WITH IDIOPATHIC PANUVEITIS: TWO CASES REPORTS

Radwan, A.^{1(*)}, Pachon, D.², Mounir, A.³ & Foster, S.^{4,5}

¹Ophthalmology dept., Hotit Bani Tamim General Hospital, Riyadh, KSA

²Oftalmosanita Uveitis Clinic, Clínica Colombia, Bogotá, Colombia

³Ophthalmology dept., Faculty of Medicine, Sohag Univ., Sohag, Egypt

⁴Massachusetts Eye Research and Surgery Institution, Weston, MA, USA

⁵Harvard Medical School, Boston, Massachusetts, USA

*E-mail: aeradwan@moh.gov.sa

Received 10/6/2018

Accepted 1/9/2018

Abstract

We report two cases of retinitis pigmentosa (RP) associated with Panuveitis in descriptive small case series. One case is RP associated with idiopathic panuveitis and the other one is RP with multifocal choroiditis and panuveitis (MCP). These are rare entities and it is very unusual for them to coexist in a patient. The first case treated with pulsed intravenous Methotrexate (MTX) 50 mg every week then stopped when inflammation was quiet with no evidence of vasculitis or papillitis on fluorescein angiogram. The second case was treated successfully with cellcept 2.5 grams daily along with vitamin A palmitate 15,000 IU daily. **Conclusion:** In patients with refractory panuveitis presenting with progressive decline in vision and visual field constriction, masquerade syndromes such as retinitis pigmentosa, must be excluded.

Keywords: Retinitis pigmentosa, Panuveitis, Methotrexate

1. Introduction

Retinitis pigmentosa is an inherited autosomal dominant, autosomal recessive, or x-linked recessive disease. Its prevalence is approximately 1 in 4000 people in the United States; however, 10-15% of patients may not be aware of symptoms until central vision is affected. At early stages, fundus examination reveals granularity or tiny focal depigmented spots in the midperiphery or far periphery. Accidentally, abnormal fundus pigmentation can be discovered in routine examination. Anterior segment, vitreous and macula

also show abnormalities in patients with RP. Posterior subcapsular opacity is common. Vitreous changes include dust like reflective particles, cells and posterior vitreous detachment [1]. Relevant workup for RP includes visual acuity testing, dark adaptometry, visual fields and electroretinogram (ERG), the later one being the gold standard for evaluating these patients. The ERG typically shows a loss or marked reduction of both rod and cone signals. Patients characteristically have delayed rod or cone b-wave implicit time or both.

Amplitude of both the a- and b- waves is reduced, since the photoreceptors are primarily involved [2]. The progression of disease symptoms occurs in a symmetrical manner, with both the left and right eyes experiencing symptoms at a similar rate [3]. Though genetic disorders in photoreceptors and retinal pigment epithelium have the main role as primary cause of

2. Studied Cases

2.1. Case 1

A 30-year-old man with a history of night blindness and decreased vision in both eyes with previous diagnosis of recalcitrant idiopathic panuveitis, retinal vasculitis, papillitis, and macular edema was referred for evaluation at Massachusetts Eye Research and Surgery Institution (MERSI). Past medical history was significant for optic neuritis years earlier. He had a history of vitrectomy in his left eye and the laboratory analysis of vitreous biopsy was unremarkable. Past treatment history included methotrexate (MTX), chlorambucil, mycophenolate

RP, recent studies have emphasized the role of inflammatory process as one of the possible factor in pathogenesis of RP [4]. Uveitis associated with RP is uncommon, but not rare. Uveitis in retinitis pigmentosa patients has been reported in many reports by various authors [5,6]. In this article, we describe two patients with retinitis pigmentosa and panuveitis.

mofetil, cyclophosphamide, and cyclosporine. On examination, the patient had best corrected visual acuity (BCVA) of 20/50 in the right eye and 20/60 in the left eye. The anterior segment examination showed Fuchs endothelial corneal dystrophy with anterior chamber (AC) +2 cells and flare in both eyes. There was mild posterior subcapsular cataract in both eyes. The posterior segment examination revealed vitreous +2 cells, perivascular retinal pigment epithelial changes and papilledema in both eyes with splinter hemorrhage in the left eye, fig. (1).

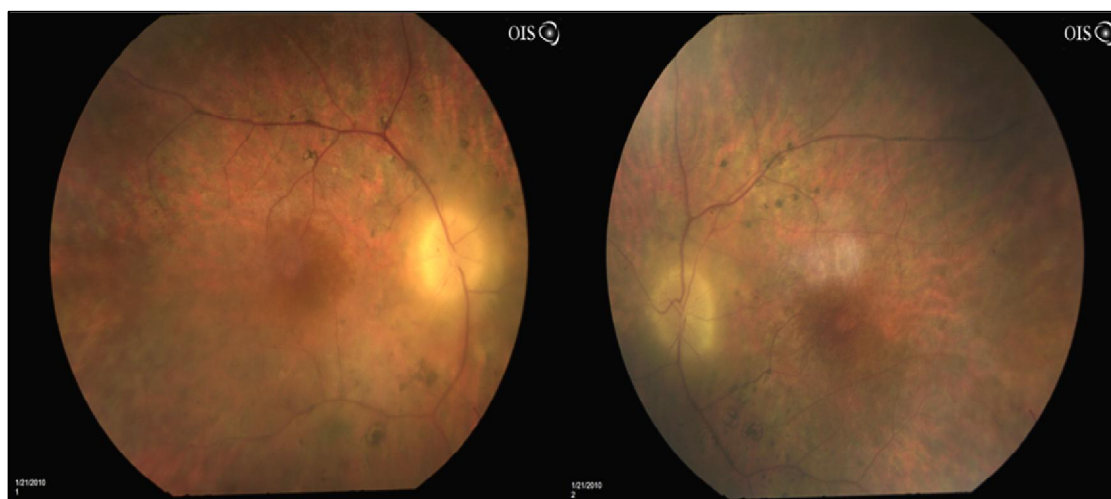


Figure (1) Color photo revealed mild perivascular retinal pigment epithelium changes in both eyes, with disc pallor and attenuated vessels.

Treatment with pulsed intravenous MTX 50 mg every week was started. His BCVA improved to 20/40 in the right eye and 20/50 in the left eye. The inflammation improved with +1 AC cells in the right eye and trace cells in the left eye. MTX infusion was stopped when

inflammation was quiet with no evidence of vasculitis or papillitis on fluorescein angiogram. Later the patient underwent cataract extraction and posterior chamber intraocular lens implantation in the right eye followed by the left eye. Postoperatively his BCVA was 20/30 in the right

eye and 20/40 in the left eye. Optical coherence tomography (OCT) showed macular edema in the right eye with central retinal thickness (CRT) of 379 μm ; while it showed macular atrophy in left eye with CRT (170 μm), which was thought to be a consequence of progressive dystrophic changes in the retina. The patient continued to have night blindness. A re-

2.2. Case 2

A 74-year-old female presented to MERSI with decreased vision in the left eye. The history dates back to 1970s, when she began to lose her vision in the right eye along with photopsia and photophobia. She consulted many doctors and, ultimately was diagnosed of having atypical RP by Dr. Elliot L. Berson. Many years later she developed multifocal choroiditis and panuveitis (MCP) in the left eye and was treated successfully with cellcept 2.5 grams daily along with vitamin A palmitate 15,000 IU daily. Our examination revealed no light perception in the right eye

and a BCVA of 20/30 in the left eye with intraocular pressure of 18 mm Hg in both eyes and sensory exotropia in the right eye. Anterior segment exam in the right eye showed a fixed dilated non reacting pupil with a mature cataract. The left eye was pseudophakic. The fundus examination of left eye disclosed vitreous 1+ cells, attenuated vessels, granular macula, normal optic disc and a diffuse atrophy in the periphery with punched out lesions in the midperiphery, fig. (2). The fundus in the right eye could not be viewed due to mature cataract.

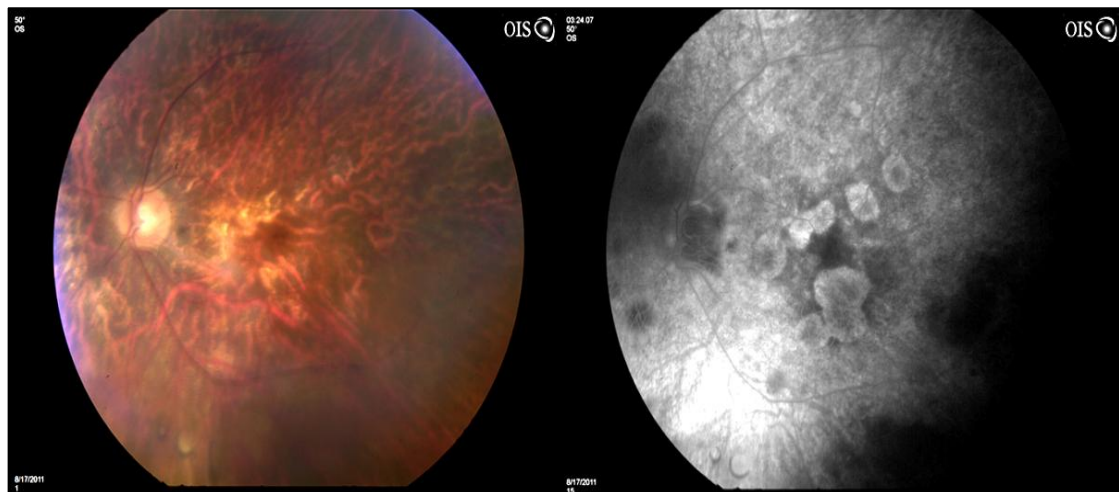


Figure (2) Color picture and FA with diffuse atrophy in the periphery and a punched out white lesion in the mid periphery

The left eye had constricted visual field, fig. (3); and the ERG showed marked decrease in the amplitude (1.05 microvolt) and delayed implicit time of 39 milliseconds, fig. (4). OCT left eye showed macular edema with CRT of 246 μm . Our impression was that the patient had MCP along with atypical RP with slight

progression of left eye on serial visual fields and ERGs. However due to the presence of the vitreous cells she was continued on Mycophenolate mofetil and Bromfenac 0.09% eye drops left eye along with vitamin A palmitate. Repeated Goldman fields and ERG every year to monitor progress was recommended.

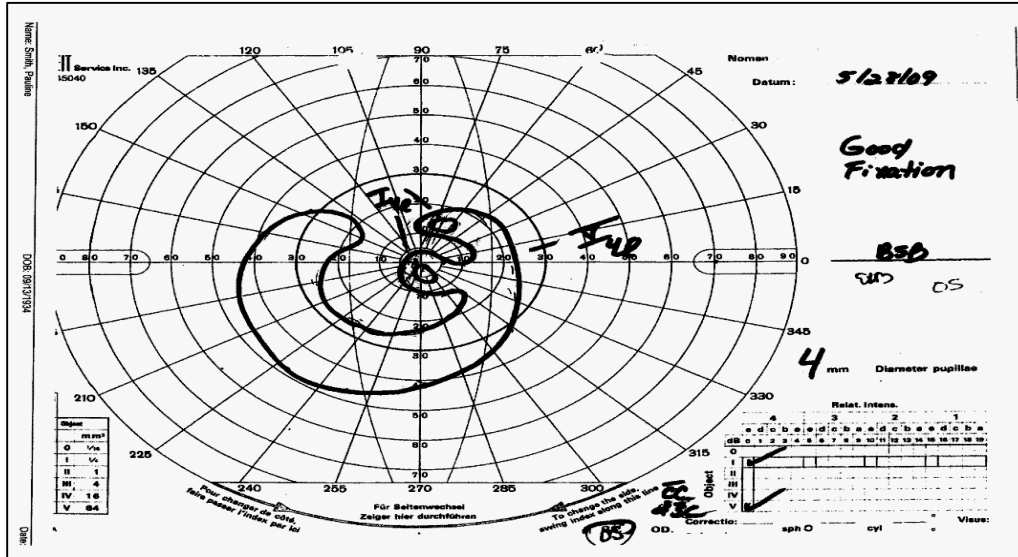


Figure (3) Abnormal I4e and V4e isopters evidencing constricted Goldman visual field OS

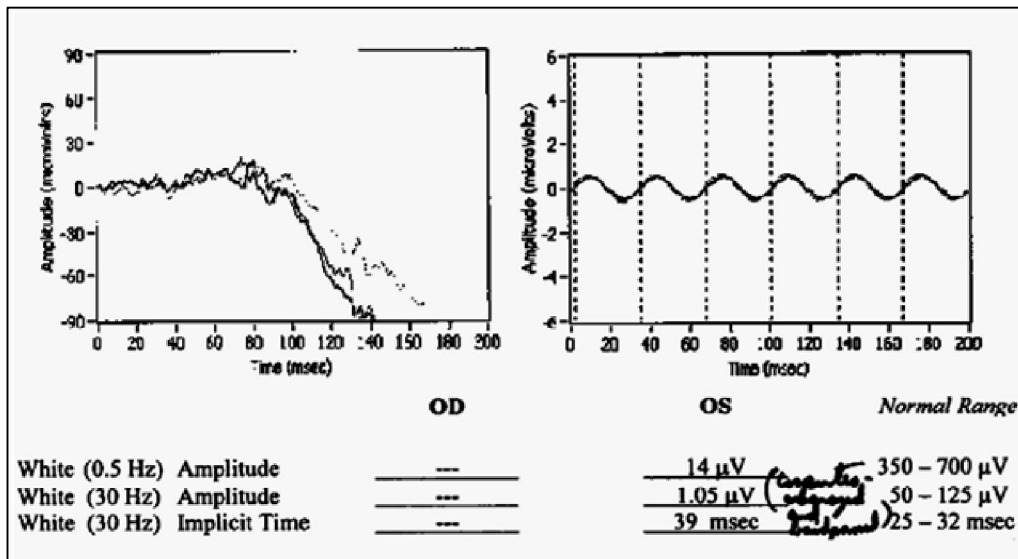


Figure (4) Photopic 30 HZ Flicker ERG with decrease of the amplitude and delayed implicit time OS.

3. Discussion

Retinitis pigmentosa (RP) is a degenerative disease with progressive nature, often presenting in early years of life. While many patients rapidly suffer progression to legal blindness, others may have relatively good central vision for decades [7]. In this case report, we presented two cases of RP meeting all criteria of panuveitis and MCP, respectively [8]. Recently, 22 patients with retinitis pigmentosa reported to have anterior and intermediate uveitis only. To our knowledge these two cases described here are the first reports of

the coexistence of RP and panuveitis. Posterior subcapsular cataract and vitreous cells are known associations of RP [9]; although association with anterior chamber inflammation, vasculitis, choroiditis and papillitis are quite rare. Panuveitis and vasculitis in the first case, failed various immunomodulatory treatments but responded to the intravenous infusion better than oral, this might be due to significant attenuation of retinal blood vessels. There are several reports have found significant inflammation in anterior chamber and vitreous cavity of

RP patients [10,11]. In the second case we suspected that the patient may had uveitis in the right eye, which led to the retinal degeneration. The retinal features of chronic panuveitis and atypical RP may mimic each other and can act as a masquerade. Clinicians must have a high index of suspicion of possible

underlying RP in patients with persistent visual loss with bilateral ocular inflammation and minimal pigment changes [12]. We reported two cases of a rare association of RP with panuveitis. Additional examination and retinal function evaluation are important in clarifying the condition and excluding other diagnosis.

4. Conclusion

In patients with refractory panuveitis presenting with progressive decline in vision and visual field constriction, masquerade syndromes such as retinitis pigmentosa, must be excluded. However, in the event that uveitis masquerade is excluded, the possibility of co-existent RP and genuine uveitis must be considered, in which case immunomodulatory therapy may be used.

References

1. Berson, E. Electroretinographic findings in retinitis pigmentosa. *Jpn J Ophthalmol.* 1987; 31 (3): 327-348.
2. Lines, M., Hebert, M., McTaggart, K., Flynn, S., Tennant, M., MacDonald, I. Electrophysiological and phenotypic features of an autosomal cone-rod dystrophy caused by a novel CRX mutation. *Ophthalmology* 2002; 109 (10): 1862-1870.
3. Hartong, D., Berson, E., Dryja, T. Retinitis pigmentosa. *Lancet* 2006; 368: 1795-1809.
4. DuttaMajumder, P., Menia, N., Roy, R. Sen, P., George, A., Ganesh, S., Biswas, J., Uveitis in patients with retinitis pigmentosa: 30 Years' Consecutive Data. *OculImmunolInflamm* 2017; 29: 1-6.
5. Alzuhairy. S., Alfawaz, A. Nongranulomatous anterior uveitis in a patient with usher syndrome. *Saudi J. Ophthalmol.* 2013; 27 (4): 295-298.
6. Díez-Cattini, G., Ancona-Lezama, D., Valdés-Lara, C, Morales-Cantón, V. The unusual association of inverse retinitispigmentosa and Fuchs' heterochromic iridocyclitis. *Int. J. Retina Vit.* 2017; 23.
7. Rimoin D, Pyeritz R, Korf B, Emery and rimoin's principles and practice of medical genetics. In: Shankar, S. (Ed.) Hereditary retinal and choroidal dystrophies. Academic Press, Cambridge, 2013; 1-18.
8. Kedhar, S., Thorne, J., Wittenberg, S., Dunn, J., Jabs, D. Multifocal choroiditis with panuveitis and punctate inner choroidopathy: Comparison of clinical characteristics at presentation. *Retina.* 2007; 27 (9): 1174-1179.
9. Heckenlively, J., Yoser, S., Friedman, L., Oversier, J. Clinical findings and common symptoms in retinitis pigmentosa. *American J. of Ophthalmology.* 1988; 105 (5): 504-511
10. Yoshida, N., Ikeda, Y., Notomi, S., et al. Clinical evidence of sustained chronic inflammatory reaction in retinitis pigmentosa. *Ophthalmology* 2013; 120 (1): 100-105.
11. Fujiwara, K., Ikeda, Y., Murakami, Y., et al. Association between aqueous flare and epiretinal membrane in retinitispigmentosa. *Invest Ophthalmol Vis Sci.* 2016; 57 (10): 4282-4286.
12. Yao, L., Foster, C. Nonmalignant, non-infectious masquerade syndromes. In: Foster, C., Vitale, A. (Eds.) *Diagnosis and Treatment of Uveitis*. Philadelphia: W.B. Saunders Company. 2002; pp. 541-546.